



PATIENT

Gracie Vezzetti

SPECIES

Canine

BREED

Shih Tzu

SEX

FS

AGE

11yr

WEIGHT

11.8lb

INTERPRETED BY

R. McKenzie Daniel,
DVM, DABVP
(Canine and Feline)

IMAGING PERFORMED BY

Dr. Julie Vezzetti

HOSPITAL NAME

Stuga North Veterinary
Care

REFERRING VET

Dr. Julie Vezzetti

INVOICE

24180

DATE

03/13/2026

PRESENTING CLINICAL SIGNS

- History of liver disease, acute, resolved with supportive care this past summer; liver values normal now; then diagnosed and clinical for Cushings dz, LDDS verified Cushings diagnosis with suppression at 4 hours, but not suppressed at 8 hours; has been on trilostane for about 3 months. Recently she is very painful in the abdomen in the flank regions on both sides.
- Abnormal PE/Chem/CBC/UA Results: Cushings disease on treatment Painful upon abdominal palpation She had an ultrasound in October that did reveal the L adrenal enlargement.

ULTRASONOGRAPHIC EXAMINATION OF THE ABDOMEN

Urinary System

The urinary bladder was subnormal in size owing to lack of urine distension which prohibited full evaluation of the urinary bladder walls. The trigone, cystourethral junction, and visible pelvic urethra to a depth of 2 cm exhibited normal thickness and tone. Mild anechoic urine was present in the lumen with no evidence of urine/lumen sediment, mineral, or calculi.

Normal size and margination were present in the kidneys. A normal 1:3 cortex / medulla ratio and normal corticomedullary definition were maintained. The echogenicity of the cortex was similar to or slightly less than normal liver parenchyma while the medulla echogenicity was hypoechoic to the cortex with no evidence of pelvic dilation. The left kidney measured 3.7 cm in length. The right kidney measured 3.7 cm in length.

The area of the aortic trifurcation was free of pathology.

Adrenal Glands

The left adrenal gland was asymmetrically enlarged in size. Mild non-homogenous parenchyma without overt visualized parenchymal mineralization. The left adrenal gland measured 1.5 cm in diameter.

The right adrenal gland was not definitively visualized, potentially owing to suppression secondary to left adrenomegaly.

Spleen

The spleen exhibited a finely textured and homogenous parenchyma which was hyperechoic to the liver and renal cortical parenchyma. The capsule was smooth and regular without apparent expansion. The splenic vasculature at the hilus was normal in volume with no evidence of congestion or thrombosis. Acute to chronic inflammatory, neoplastic, or benign parenchyma changes were not noted.

Liver/Gallbladder

The liver presented mild to moderately enlarged in size. The parenchyma of the liver was subjectively normal in echogenicity compared to the spleen and renal cortices. The liver parenchyma was uniform with a mildly coarse echotexture. The capsule of the liver was symmetrically rounded to mildly swollen in margination. The hepatic and portal vasculature were normal in appearance without signs of



PATIENT

Gracie Vezzetti

congestion. The gallbladder was non-distended in size with mild non-organized debris. The cystic and common bile ducts were normal.

Gastrointestinal

SPECIES

Canine

The stomach presented intact wall layering with a normal wall layer ratio. The lumen of the stomach contained mild non-shadowing ingesta sonographically suggestive of food echogenicity with no signs of obstruction or foreign material.

BREED

Shih Tzu

The small intestine presented intact wall layering with 1:3 muscularis/mucosa ratio. The lumen of the small intestine was empty with no signs of mechanical/metabolic ileus, obstruction or foreign material.

Normal visible colon wall layers were present with apparent formed feces in lumen.

SEX

FS

Pancreas

The parenchyma of the left limb, body and right limb of the pancreas presented isoechoic to the adjacent omental fat. A normal curvilinear capsule contour of the pancreas was present. The visible pancreatic duct was normal. No signs of active inflammation or neoplastic disease was evident.

AGE

11yr

Free Abdomen

No omental masses, overt lymphadenopathy or peritoneal effusion was present.

WEIGHT

11.8lb

ULTRASONOGRAPHIC FINDINGS

Primary

- Left adrenomegaly with non-visualized right adrenal gland
- Benign hepatomegaly
- Mild gallbladder debris (non-mucocele)
- Static age-related renal changes
- Normal gastrointestinal tract / pancreas

INTERPRETED BY

R. McKenzie Daniel,
DVM, DABVP
(Canine and Feline)

INTERPRETATION OF THE FINDINGS & FURTHER RECOMMENDATIONS

IMAGING PERFORMED BY

Dr. Julie Vezzetti

Aside from the left adrenomegaly, no overt evidence of significant visceral pathology. Left adrenal hyperplasia, functional adenomatous change or tumor possible. Given no obvious visualized evidence of right adrenal pathology, and assuming no pathology on three view chest radiographs, abdominal CT for further assessment of the left adrenal gland and left adrenalectomy is recommended. Continued as needed hepatosupportive medications, therapy for Cushing syndrome and serial sonographic monitoring of the left adrenal gland for evidence of progressive enlargement would be a more conservative approach.

HOSPITAL NAME

Stuga North Veterinary
Care

REFERRING VET

Dr. Julie Vezzetti

INVOICE

24180

DATE

03/13/2026



PATIENT

Gracie Vezzetti

SPECIES

Canine

BREED

Shih Tzu

SEX

FS

AGE

11yr

WEIGHT

11.8lb

INTERPRETED BY

R. McKenzie Daniel,
DVM, DABVP
(Canine and Feline)

IMAGING PERFORMED BY

Dr. Julie Vezzetti

HOSPITAL NAME

Stuga North Veterinary
Care

REFERRING VET

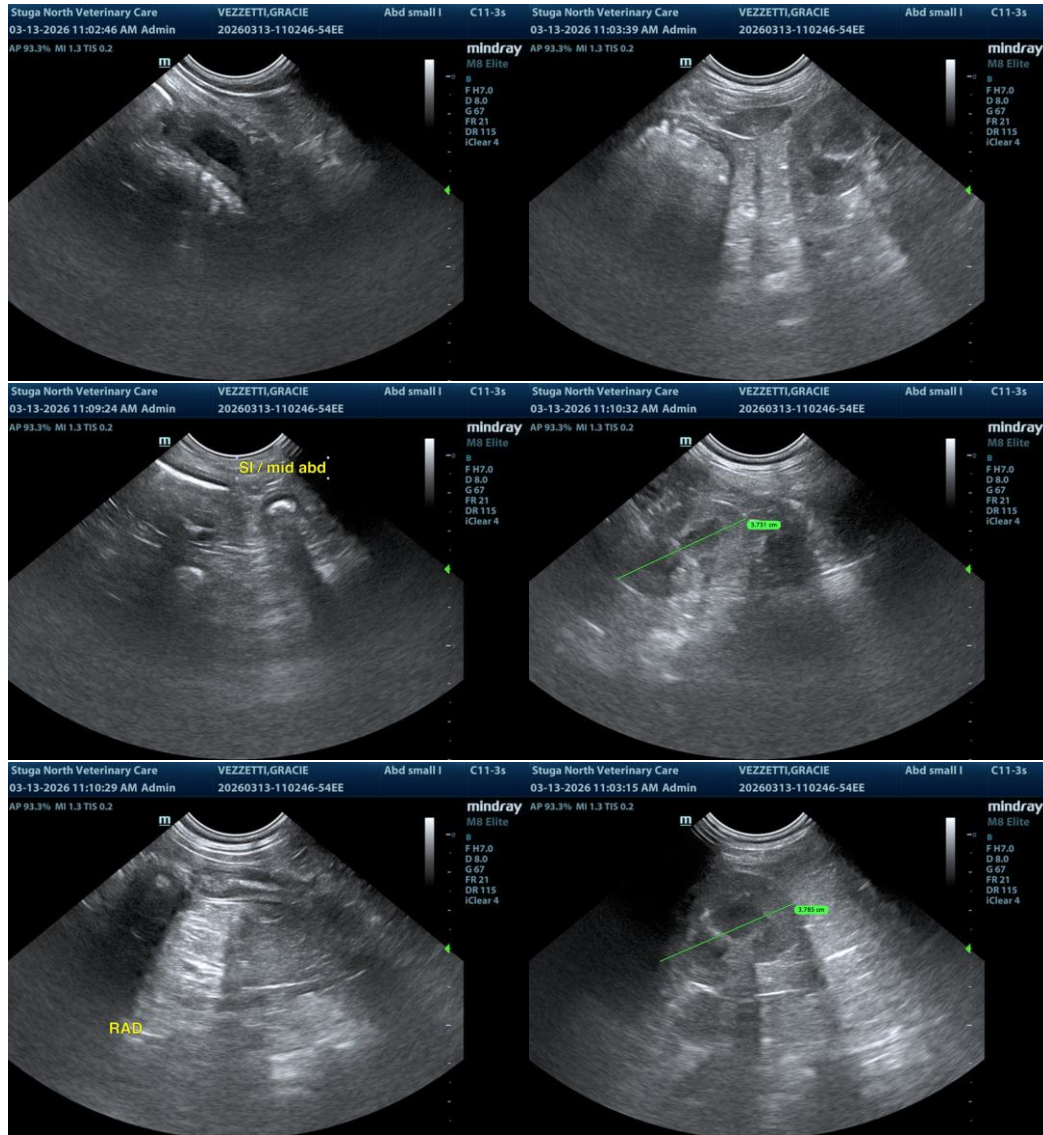
Dr. Julie Vezzetti

INVOICE

24180

DATE

03/13/2026





PATIENT

Gracie Vezzetti

SPECIES

Canine

BREED

Shih Tzu

SEX

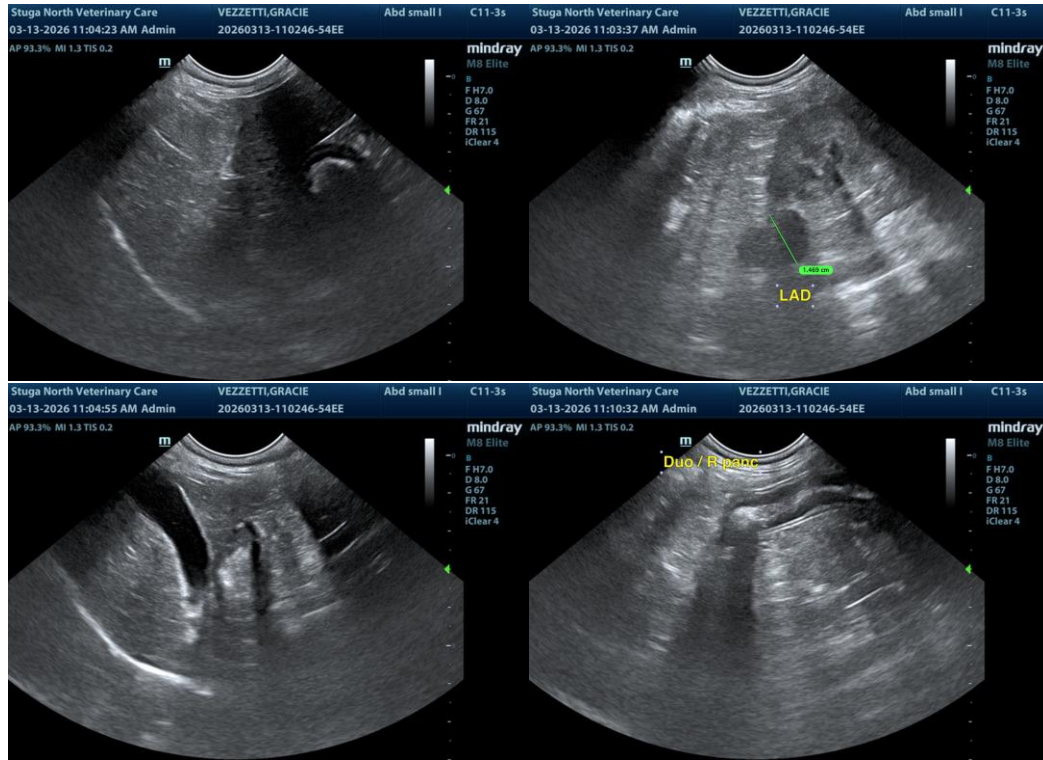
FS

AGE

11yr

WEIGHT

11.8lb



INTERPRETED BY

R. McKenzie Daniel,
DVM, DABVP
(Canine and Feline)

IMAGING PERFORMED BY

Dr. Julie Vezzetti

HOSPITAL NAME

Stuga North Veterinary
Care

REFERRING VET

Dr. Julie Vezzetti

INVOICE

24180

DATE

03/13/2026

The information and recommendations provided are based on the images presented by the referring veterinarian/sonographer. No evaluation can be communicated regarding pathology that was not visible in the image/video clips provided.

Thank you for this referral. If the clinical or image interpretation does not parallel your findings or if I can be of any further assistance, please contact me.

R. McKenzie Daniel, DVM, DABVP (Canine/Feline Practice)
info@sonopath.com